

## Nasolabial Evaluation of the Unilateral Cleft Lip Repair

Luis Bermudez, M.D.

There are several reasons to develop a standardized system to measure the surgical results in cleft lip and palate patients:

- It is very important to set a goal of what a surgeon has to achieve with the surgery, no matter what technique is used by that surgeon.
- An audit system has to be created if we want to assure the quality of care provided by any organization, hospital or physician.
- Inter-center comparison of the outcome of treatment is needed in order to truly answer the questions about treatment of cleft lip and palate patients and, finally, to make evidence based recommendations. Generating adequate samples with specific cleft subtypes treated by contrasting treatment modalities is our challenge.

As part of Operation Smile's Post Operative Program an evaluation system of the Unilateral Cleft Lip Repair has been developed. Here we explain the bases of the Nasolabial Evaluation System of the Unilateral Cleft Lip Repair.

It is clear that if we want to measure the real surgical outcomes we have to follow up with the patients for a long time. As we collect the data in a long term follow up, we can measure the early outcome in order to audit the results and potentially generate some early conclusions.

The Nasolabial Evaluation of the Unilateral Cleft Lip Repair has been divided into:

1. Very Early Outcome:
  - a. As soon surgery ends, before administering ointment or taking out the mouth gag.
  - b. Six to ten days post operative.
2. Early Outcome: six month to one year postoperative.
3. Late Outcome: five years postoperative.

The very early and early outcomes are very important from the auditing point of view. One of the questions to be answered will be: Are the very early outcome, the early outcome and the late outcome significantly different?

In plastic surgery it is not easy to evaluate objectively the results obtained. After a unilateral cleft lip repair there are several ways and variables that could be evaluated in the nasolabial area. But we have to be very careful to avoid losing the north; we have to consistently evaluate what really matters. The qualitative assessment of the nasolabial appearance has been used as a reliable system of evaluation of the surgical outcomes, allowing outcomes comparisons between centers (1,2,3.)

There are limitations of still photography, but using moving images (4) or complex computerized systems would raise the level of complexity and the

burden, without solving the real obstacles in the clinical research of cleft lip and palate treatment. It is not a lack of technology which has prevented the accumulation of evidence based knowledge about cleft lip and palate treatment; the real obstacles were described by Shprintzen (5) in 1991 as: The real researcher's motivations, Sample selection, Problems related to population Heterogeneity, Impatience, Samples of twenty or thirty, Lack of statistical forethought, Holding variables constant, Definitions of success, Interpretation of results.

The final goal in the unilateral cleft lip repair is to restore the anatomy of the lip and nose as symmetrical as possible. The range of outcome for that surgical repair could be considerable and is related to particular surgical techniques, the skill of individual surgeons, or programs of surgery.

The initial deformity is one of the most important factors determining the result. In 1991 Montier et al. (6) proved how the postoperative result scores in the most serious clefts were significantly worse than those of the least serious clefts. It is no wonder, then, that it is rare to see in the medical literature surgeons using pictures of severe clefts when they are describing new "techniques" of modifications. The evaluation of the result obtained has to include the initial deformity.

We have developed a dual rating system with two scores: one preoperative score concerning the severity of cleft and one score for the postoperative results.

Severity of cleft Severity of cleft will be rated as mild, moderate or severe in accordance with Table 1.


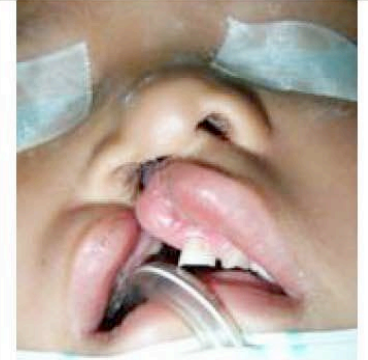
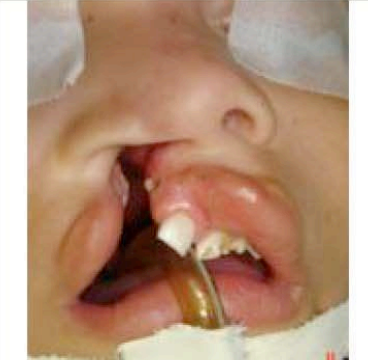
<p><b>Mild</b> Incomplete clefts.</p>	<p><b>Moderate</b> Complete but not wide cleft. <i>There is some contact between the edges of cleft in rest.</i></p>	<p><b>Severe</b> Complete and wide cleft. <i>There is not any contact between edges of cleft in rest.</i></p>
1	2	3
		

Table 1 Classification of the severity of clefts

#### Post-operative Result:

Five features of the nasolabial area will be evaluated separately (see figure 2):

1. Symmetry at the Cupid's bow. The Cupid's bow peaks should be on the same horizontal plane.
2. Nasal symmetry. It is a qualitative evaluation of the nasal shape.
3. Symmetry of the lateral lip. The distance from the alar base to white roll has to be symmetrical, also the angle of that lateral white roll.
4. Symmetry of the free vermillion. The free border of the lip has to be a continuous smooth curved line with no notch or bulginess.
5. Symmetry of the dry vermillion. The red line should be a continuous with a normal wet and dry vermillion relationship.

This five-feature assessment will be rated using a simple three-point scale:

0 = Indicates a poor or a very poor result

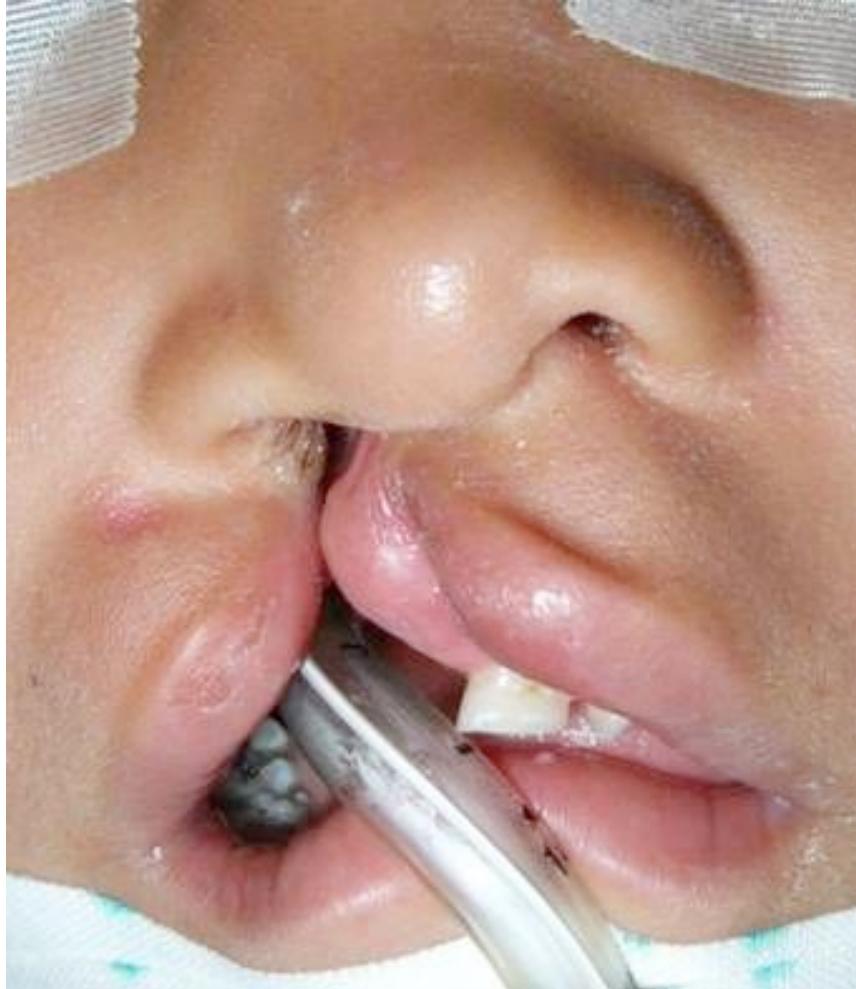1 = Indicates a fair outcome

2 = Indicates a good or very good outcome.

A pattern with clinical examples was developed to be used as a guide during the evaluation (Figure 3).

In the appendix you can see how this measurement system is used to evaluate some clinical cases. In clinical cases 1, 2 and 3 we evaluated the preoperative deformity and the surgical outcome. In clinical cases 4 and 5 we just evaluated the surgical outcome. The analysis of unfavorable outcomes even if we do not have the preoperative data is a very important source of knowledge; our final goal has to be improve the surgical outcomes in Operation Smile.

**Figure 1**  
**INITIAL DEFORMITY**

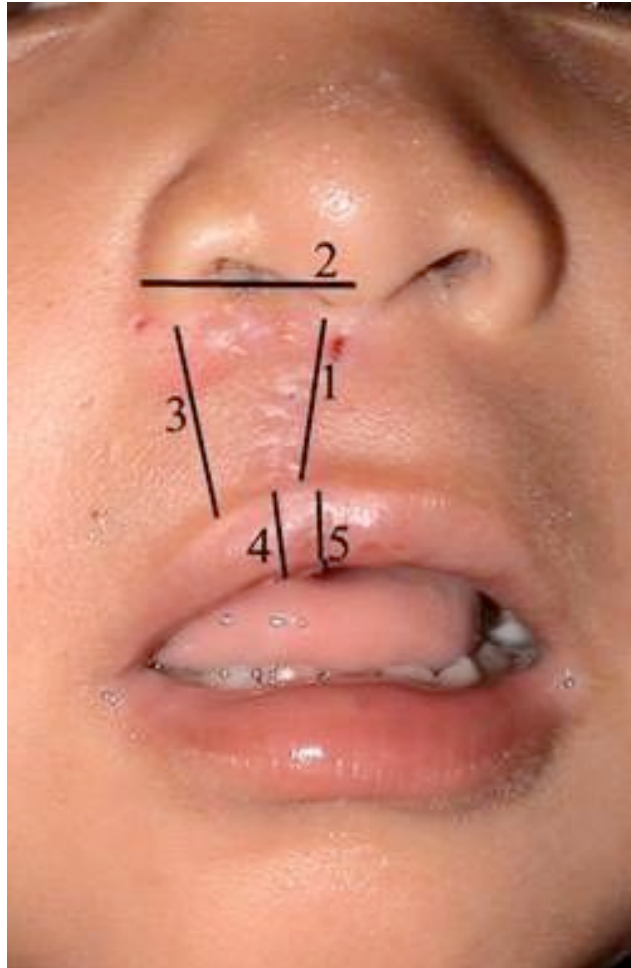


*Pre-operative picture just before surgery.*

### **GOALS OF THE UNILATERAL CELFT LIP REPAIR**

- Create a symmetrical lip and nose.
- Restore cleft lip length.
- Functional repair of the orbicularis oris muscle.
- Reconstruct the floor of the nose.
- Recreate wet and dry vermilion relationship
- Correct the flaring of the alar base.
- Correct the dome of the nose.
- Create a columella of equal length on both sides
- Hide scar in natural line

**Figure 2**  
**REPAIRED UNILATERAL CLEFT LIP**












*Post-operative picture taken 9 days after cleft lip repair.*



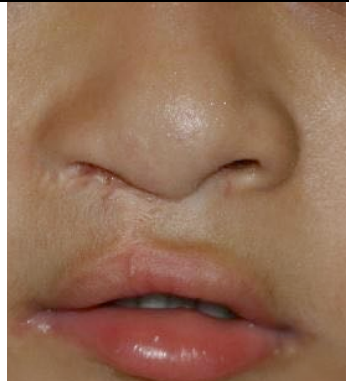



### **FEATURES EVALUATED OF THE NASOLABIAL AREA**

In this picture taken one week post operative to patient shown in figure 1, we can see the features evaluated. In a previous study (1,) it has been found that judgment of the nasolabial could be biased by other facial features unrelated with the cleft itself; so the picture has to be trimmed leaving just the nasolabial area.

1. Symmetry at the Cupid's bow. Distance from the base of the columella to bow's peak.
2. Nasal symmetry. The shape of nostril, the dome of nose and the distance from the midline of the columella to the alar base.
3. Symmetry of lateral lip. Distance from the alar base to white roll and angle of white roll.
4. Symmetry of the free vermilion. Two measurements should be considered; distance from the Cupid's bow to free vermilion and from the columella base to free vermilion.
5. The wet and dry vermilion relationship.

**Figure 3.**  
**FEATURES EVALUATED AND QUALIFICATION**

	0 Poor result Very poor result	1 Fair	2 Good Result Very good result.
<p>Symmetry at the Cupid's bow.</p> <p>Distance from the base of the columella to bow's peak.</p>	 Huge discrepancy of more than 2 mm (about).	 There is some discrepancy between about 1-2 mm.	 There is not discrepancy or it is less than about 1 mm.
<p>Overall nasal Symmetry.</p> <p>The shape of nostril, the dome of nose and the distance from the midline of the columella to the alar base.</p>	 It is <u>completely</u> asymmetrical.	 There is some symmetry but there is a noticeable difference between both sides.	 Symmetrical or mostly symmetrical.
<p>Symmetry of the lateral lip</p> <p>The distance from the alar base to white roll has to be symmetrical, also the angle of that lateral white roll.</p>	 There is a severe asymmetry in the length of the lateral lip and the angle of white roll.	 There is a small asymmetry in the length of the lateral lip.	 Length of the lateral lip and angle of the white roll are symmetrical.

<p><b>Symmetry of free vermillion</b></p> <p>The free border of the lip has to be a continuous smooth curved line with no notch or bulginess.</p>	 <p>There is a clear notch and asymmetry.</p>	 <p>There is a small notch and a small bulginess in the free vermillion.</p>	 <p>There is a continuous smooth curved line.</p>
<p><b>Wet and dry vermillion relationship.</b></p> <p>The red line should be a continuous with a normal wet and dry vermillion relationship.</p>	 <p>Severe discrepancy in the wet/dry vermillion relationship.</p>	 <p>There is some mismatch in the red line.</p>	 <p>There is not a noticeable mismatch in the red line.</p>

## REFERENCES

1. Asher-McDade C, Roberts CT, Shaw WC, Gallagher C. The development of a method for rating nasolabial appearance in patients with clefts of the lip and palate. *Cleft Palate Craniofac J* 1991; 28; 385-391.
2. Asher-McDade C, Brattstrom V, Dahl E, McWilliam J, Molsted K, Plint D, Prah-Andersaen B, Semb G, Shaw W. A six-center international study of treatment outcome in patients with clefts of the lip and palate: Part 4. Assessment of nasolabial appearance. *Cleft Palate Craniofac J* 1992;29; 409-412.
3. Brattstrom V, Molsted K, Phral-Andersen B, Semb G, Shaw W. The Eurocleft study: Intercenter study of treatment outcome in patients with complete cleft lip and palate. Part 2: Craniofacial form and Nasolabial Appearance. *Cleft Palate Craniofac J* 2005; 42; 69-77.
4. Marrant DG, Shaw WC. Use of standardized video recordings to assess cleft surgery outcome. *Cleft Palate Craniofac J* 1996;33; 134-142.
5. Shprintzen RJ. Fallibility of Clinical Research. *Cleft Palate Craniofac J*. 1991; 28; 136-140.
6. Mortier PB, Martinot VL, Anastassov Y, Kulik JF, Duhamel A, Pellerin PhN. Evaluation of the results of cleft lip and palate surgical treatment: Preliminary report. *Cleft Palate Craniofac J*. 1997; 34; 247-255
7. Bermudez L., Lizarraga A. Operation Smile: How To Measure Its Success. *Annals Of Plastic Surgery* September 2011, Volume 67, Issue 3, Pp 205-208.
8. [Bermudez L, Carter V, Magee W, Sherman R, Ayala R. Surgical outcomes auditing systems in humanitarian organizations. \*World J Surg\* 34: 3; 403-410. March 2010.](#)
9. [Bermudez I, Trost k, Ayala r. Investing in a surgical outcomes auditing system. \*Plastic Surgery International\*. Volume 2013, article id 671786 .](#)



